



Improvement in primary resection accuracy with Image Free Robotic Assisted Total Knee Arthroplasty compared to Navigation

Gary Doan¹, Andrew Van Avery¹, Patrick Curtis¹, Ian Leslie¹, Dan Hoeffel¹, and Chadd Clary²

¹DePuy Synthes, Raynham, MA

²University of Denver, Denver, CO

GDoan@its.jnj.com, AVanAver@its.jnj.com, pcourtis@its.jnj.com, ilesliel@its.jnj.com, dhoeffel@its.jnj.com, Chadd.Clary@du.edu

Abstract

Aims: Several studies have been performed that compare the accuracy of Robotic-Assisted Total Knee Arthroplasty (RATKA) to conventional instrumentation as well as navigation to conventional instrumentation, yet there is a lack of studies comparing RATKA to navigation. The purpose of this study is to evaluate the accuracy of a contemporary image free navigation system for TKA in a cadaveric study using the same methodology as used previously to assess the accuracy of a RATKA system and conventional instrumentation. **Methods:** Four orthopaedic surgeons performed bi-lateral TKA on 18 pelvis-to-toe cadaveric specimens without implantation using the BrainLab Knee3 navigation system. Preoperative and postoperative computed tomography (CT) scans were taken to assess the resection accuracy of the navigation system relative to the planned alignment targets recorded intraoperatively. **Results:** The mean error in femoral coronal angle was $1.08^\circ \pm 0.87^\circ$ compared to $1.39^\circ \pm 0.95^\circ$ conventional and $0.63^\circ \pm 0.50^\circ$ RATKA; the differences between navigation and RATKA were statistically significant. The mean error in the tibial coronal angle was $1.24^\circ \pm 1.13^\circ$ compared to $1.65^\circ \pm 1.29^\circ$ conventional and $0.93^\circ \pm 0.72^\circ$ RATKA. The mean error in femoral flexion was $2.13^\circ \pm 1.87^\circ$ compared to $3.27^\circ \pm 2.51^\circ$ conventional and $1.21^\circ \pm 0.90^\circ$ RATKA; the differences between navigation and manual and navigation and RATKA were statistically significant. The mean errors in the femoral rotation (navigation $1.30^\circ \pm 1.38^\circ$, conventional $1.00^\circ \pm 0.70^\circ$, RATKA $1.04^\circ \pm 0.81^\circ$) and tibial slope (navigation $1.89^\circ \pm 1.28^\circ$, conventional $1.63^\circ \pm 1.39^\circ$, RATKA $1.62^\circ \pm 1.13^\circ$) were similar between the groups. **Conclusion:** This study showed that for some metrics navigation improves resection accuracy compared to conventional instrumentation and RATKA further improves resection accuracy compared to CAS.

1 Introduction

Reducing the number of revisions is important in total knee arthroplasty (TKA) and postoperative results can be influenced by the accuracy of primary resections. As advancements in technology has progressed, there has been a rise in the use of navigation for TKA and robotic-assisted total knee arthroplasty (RATKA) in an attempt to improve accuracy. Several studies have been performed that compare the accuracy of RATKA to conventional instrumentation^{1,2} as well as navigation to conventional instrumentation^{3,4,5}, yet there is a lack of studies comparing RATKA to navigation. The purpose of this study is to evaluate the accuracy of a contemporary image free navigation system for TKA in a cadaveric study using the same methodology as used previously to access the accuracy of a RATKA system and conventional instrumentation.¹ Generating this data allowed for a direct resection accuracy comparison between navigation, RATKA, and conventional instrumentation.

2 Methods

2.1 Data Collection

Four out of five orthopaedic surgeons from a previous study¹ had varying levels of experience with navigation and performed bi-lateral TKA on 18 pelvis-to-toe specimens (Age: 70.4 ± 8.2 year, [Range 47 – 80 years], Height: 67.1 ± 4.1 in. [Range 60 – 75 in.], Weight: 132.4 ± 35.8 lbs. [Range 80 – 246 lbs.], BMI: $20.6 - 4.9$ [Range 13.3 – 33.4]) using the BrainLab Knee3 navigation system. Prior to surgery, CT scans were taken of the lower limbs to define an accurate model for measurements but were not used for the surgery.

Surgeons used the Knee3 software to acquire anatomic landmarks, plan the procedure, and the intraoperative targets were recorded for the femoral coronal angle (FCA), femoral sagittal angle (FSA), femoral internal-external rotation angle (FRA), tibial coronal angle (TCA), and tibial sagittal angle (TSA). A postoperative CT scan was taken to capture the resected bone surfaces using the same protocol as the preoperative CT scan.

2.2 Resection Angle Assessment

The bony anatomy was segmented from the preoperative CT scan to define anatomic landmarks and build an independent coordinate system from the navigation system. The superior-inferior axis of the femur was defined as the femoral mechanical axis and was rotationally aligned to the posterior condylar axis. The superior-inferior axis of the tibia was defined as the tibial mechanical axis and was rotationally aligned to the medial third of the tibia tubercle.

The postoperative CT scan was also segmented, and the femoral distal, femoral posterior, and tibial resection surfaces were fit with a plane. To calculate FSA and FCA, an angle between the femoral distal resection plane and the femoral superior-inferior axis was calculated in the sagittal and coronal plane, respectively. To calculate FRA, an angle between the femoral posterior resection plane and the femoral anterior-posterior axis in the transverse plane was calculated. Similar calculations were performed for TSA and TCA with the tibial resection surface and the sagittal and coronal plane, respectively.

The calculated resection angles were compared to the surgeons plans on the navigation software. This allowed for independent quantification of system accuracy without relying on the navigation system's established coordinate system and ensures errors from the full system were captured. The results of this study were compared to the results of the previous study on the VELYS™ Robotic-Assisted Solution and conventional instrumentation using the same accuracy assessment

methodology. Two-sample one tailed t-tests with a significance level of 5% ($\alpha = 0.05$) were performed to determine statistically significant differences of the absolute errors between RATKA, navigation, and conventional instrumentation.

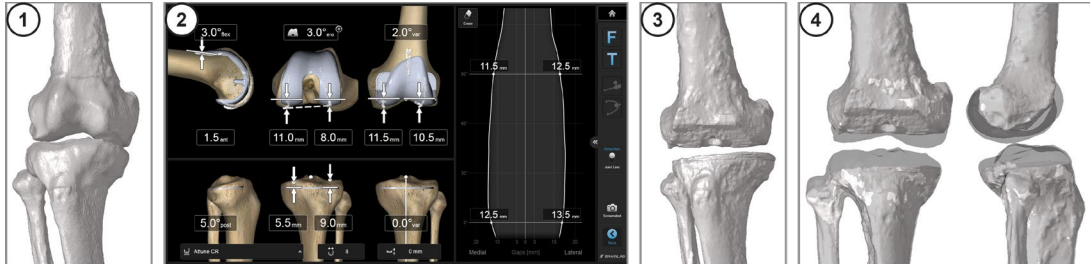


Figure 1: Methodology overview, 1 – preoperative CT scan, 2 – example plan on the navigation system, 3 – postoperative CT scan, 4 – registration of preoperative and postoperative CT scans for assessment

Results

The navigation system was found to be highly accurate with mean absolute errors ranging from 1.08 ± 0.87 degrees (FCA) to 2.13 ± 1.87 degrees (FSA). When compared to the other systems, the mean absolute errors for FCA, FSA, and TCA of the navigation system were lower than conventional instruments but higher than RATKA. The difference between the navigation and conventional cohort was statistically significant for FSA only. The difference between navigation and RATKA was statistically significant for the FCA and FSA. The mean absolute errors for the FRA and TSA were similar between the three methodologies (Figure 2).

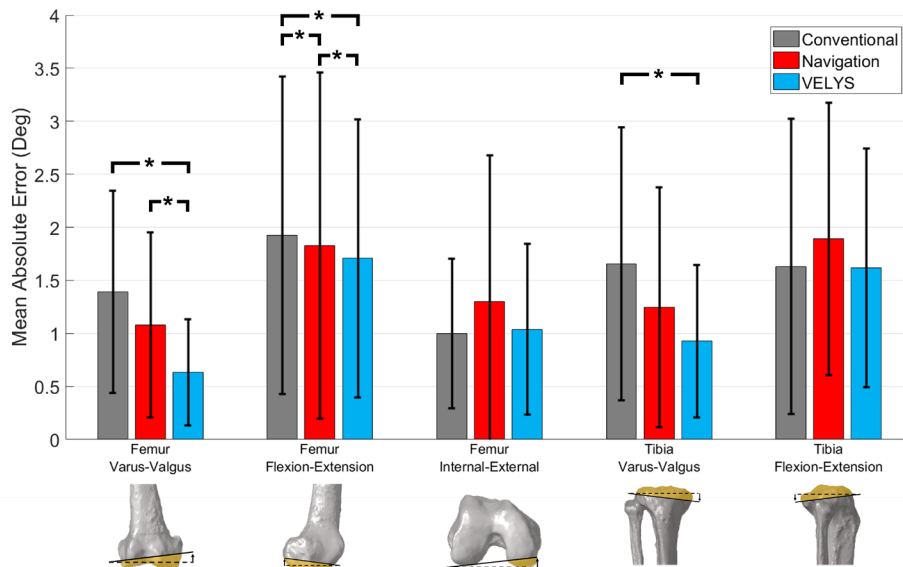


Figure 2: Mean differences between target and measured resection angles (Mean Absolute Error) for conventional instruments, navigation, and VELYS (RATKA) cohorts. Statistically significant ($p \leq 0.05$) differences are identified with ‘*’.

Discussion

The use of navigation systems has previously been shown to improve the accuracy of bone resections and implant positioning compared to conventional instrumentation in clinical studies.^{3,5} The VELYS Robotic-Assisted Solution has been able to demonstrate further improvements in accuracy compared to navigation in some of the metrics assessed. The relative accuracy of conventional instruments, navigation and VELYS Robotic-Assisted Solution follow a logical progression. The use of the navigation coordinate system to guide the position of the cutting blocks results in a favorable trend in accuracy for navigation compared to conventional, whilst RATKA allows a more precise execution of the plan compared to navigation. The difference in accuracy between RATKA and navigation can potentially be explained by two contributing factors:

1. With navigation the surgeon is required to position and pin the cutting blocks to the bone according to the guidance on screen; this can be challenging to achieve precisely in all planes with the surgeon often accepting a small amount of error in one or both planes (e.g. +/- 1 degree).
2. The bone resections are executed through the cutting block slot where play between the saw blade and slot can introduce further errors.

With RATKA both potential sources of error are removed as the end effector of the system is directly connected to an oscillating saw which is driven to the correct orientation and position, defined by the plan, and maintained within the cutting plane during the resection.

References

- [1] Doan GW, Curtis RP, Wyss JG, Green EW, Clary CW. Image-Free Robotic-Assisted Total Knee Arthroplasty Improves Implant Alignment Accuracy: A Cadaveric Study. *Journal of Arthroplasty* 2022. <https://doi.org/10.1016/j.arth.2021.12.035>.
- [2] Agarwal N, To K, McDonnell S, Khan W. Clinical and Radiological Outcomes in Robotic-Assisted Total Knee Arthroplasty: A Systematic Review and Meta-Analysis. *Journal of Arthroplasty* 2020. <https://doi.org/10.1016/j.arth.2020.03.005>. Epub 2020 Mar 11.
- [3] Hetaimish BM, Khan MM, Simunovic N, Al-Harbi HH, Bhandari M, Zalzal PK. Meta-analysis of navigation vs conventional total knee arthroplasty. *Journal of Arthroplasty* 2012. <https://doi.org/10.1016/j.arth.2011.12.028>. Epub 2012 Feb 13. PMID: 22333865.
- [4] Blakeney WG, Khan RJ, Wall SJ. Computer-assisted techniques versus conventional guides for component alignment in total knee arthroplasty: a randomized controlled trial. *Journal of Bone & Joint Surgery* 2011. <https://doi.org/10.2106/JBJS.I.01321>. PMID: 21915542.
- [5] Brin YS, Nikolaou VS, Joseph L, Zukor DJ, Antoniou J. Imageless computer assisted versus conventional total knee replacement. A Bayesian meta-analysis of 23 comparative studies. *Int Orthop* 2011;35:331–9. <https://doi.org/10.1007/s00264-010-1008-6>.